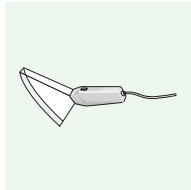
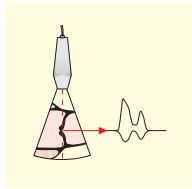


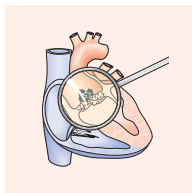
Contents



Examination	2
Imaging and Patient Position	2
Parasternal Long-Axis View	8
Parasternal Short-Axis View	14
Apical Windows	26
Suprasternal Window	36
Subcostal Window	40



M-Mode and Doppler Echocardiography	42
M-Mode Echocardiography	44
Doppler Echocardiography	48



Cardiac Abnormalities	76
Valvular Heart Disease	78
Coronary Heart Disease	132
Cardiomyopathies	150
Prosthetic Valves	164
Carditis	180
Septal Defects	194
Hypertensive Heart Diseases	204
Intracardiac Masses	212